



A Case of Diffuse Infiltrative Hepatocellular Carcinoma with Marked Response to Sorafenib Treatment Evidenced by ¹⁸F-FDG PET/MRI

¹⁸F-FDG PET/MRG ile Sorafenib Tedavisine Belirgin Yanıt Verdiği Gösterilen Diffüz İnfiltratif Hepatosellüler Karsinom Olgusu

Elgin Özkan¹, Burak Demir¹, Diğdem Kuru Öz², Yüksel Ürün³, Nuriye Özlem Küçük¹

¹Ankara University Faculty of Medicine, Department of Nuclear Medicine, Ankara, Türkiye

²Ankara University Faculty of Medicine, Department of Radiology, Ankara, Türkiye

³Ankara University Faculty of Medicine, Department of Internal Medicine, Division of Medical Oncology, Ankara, Türkiye

Abstract

A 73-year-old woman with known diagnosis of chronic hepatitis B infection referred for ¹⁸F-fluorodeoxyglucose positron emission tomography/computed tomography (¹⁸F-FDG PET/CT) and magnetic resonance imaging (MRI) after detection of a liver mass with 9 cm diameter in contrast enhanced CT. However, ¹⁸F-FDG PET/CT and MRI revealed diffuse infiltrating hepatocellular carcinoma lesions other than previously defined mass. After 9 months of Sorafenib treatment serum alpha fetoprotein levels dropped from 60,500 ng/mL to 801 ng/mL. Later ¹⁸F-FDG PET/MRI was performed for evaluation of response to treatment and revealed marked response to treatment.

Keywords: Hepatocellular carcinoma, positron emission tomography, fluorodeoxyglucose, magnetic resonance imaging, sorafenib

Öz

Bilinen kronik hepatit B enfeksiyonu tanılı hasta kontrastlı bilgisayarlı tomografide (BT) karaciğerde 9 cm boyutlu kitle saptanması üzerine ¹⁸F-florodeoksiglukoz pozitron emisyon tomografisi/BT (¹⁸F-FDG PET/BT) ve manyetik rezonans görüntüleme (MRG) için yönlendirildi. Ancak, ¹⁸F-FDG PET/BT ve MRG'de önceki tanımlanan kitle dışında parankimde diffüz infiltratif hepatosellüler karsinom lezyonları saptandı. Dokuz aylık sorafenib tedavisini takiben serum alfa fetoprotein değerleri 60.500 ng/mL'den 801 ng/mL'ye kadar geriledi. Tedavi yanıtı için çekilen ¹⁸F-FDG PET/MRG'de de belirgin tedavi yanıtı gösterildi.

Anahtar kelimeler: Hepatosellüler karsinom, pozitron emisyon tomografisi, florodeoksiglukoz, manyetik rezonans görüntüleme, sorafenib

Address for Correspondence: Burak Demir, MD, Ankara University Faculty of Medicine, Department of Nuclear Medicine, Ankara, Türkiye

Phone: +90 312 595 64 45 **E-mail:** 4burakfe@gmail.com **ORCID ID:** orcid.org/0000-0002-0966-9988

Received: 26.01.2024 **Accepted:** 03.03.2024 **Epub:** 16.04.2024



Copyright© 2024 The Author. Published by Galenos Publishing House on behalf of the Turkish Society of Nuclear Medicine. This is an open access article under the Creative Commons Attribution-NonCommercial-NoDerivatives 4.0 (CC BY-NC-ND) International License.

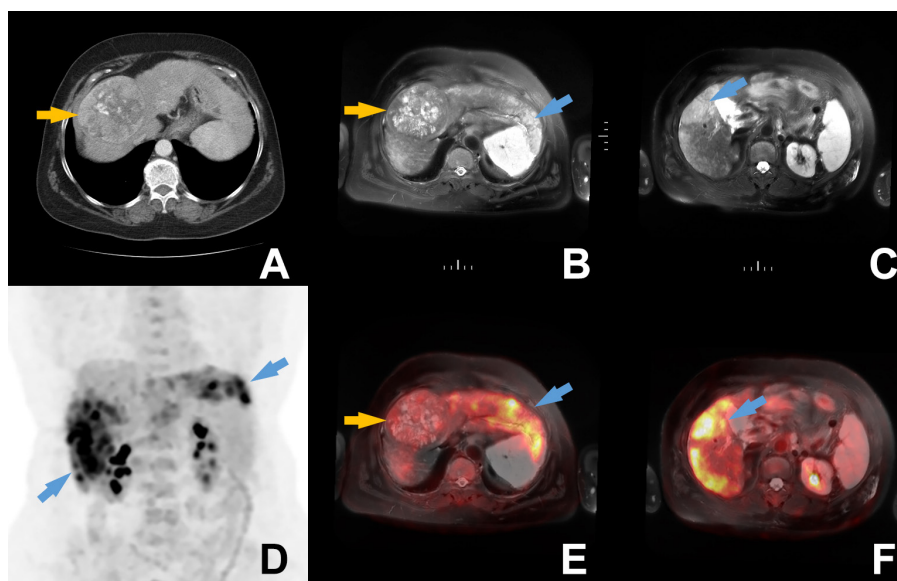


Figure 1. A 73-year-old woman with hepatitis B infection presented with abdominal pain and dynamic liver computed tomography (CT) revealed a 9 cm lesion in the liver (A, orange arrow). The patient's serum alpha feto protein (AFP) levels were measured as high as 60,500 ng/mL. The patient was referred for ^{18}F -fluorodeoxyglucose positron emission tomography/CT (^{18}F -FDG PET/CT) and magnetic resonance imaging (MRI) for staging of probable hepatocellular carcinoma (HCC) diagnosis. However, ^{18}F -FDG PET/CT and MRI revealed diffuse infiltrating HCC lesions in both lobes of liver in addition to the previously defined 9 cm mass. The diffuse infiltrating lesions (blue arrows) were hyperintense in axial T2-weighted MRI (B, C) images and showed intense ^{18}F -FDG uptake with maximum standardized uptake value (SUV_{max}): 12.5 as visualized in the maximum intensity projection (MIP) (D), axial PET/CT MRI fusion images (E, F). Additionally, the previously defined 9 cm lesion (orange arrows) had very mild ^{18}F -FDG uptake. Sorafenib treatment was initiated after the detection of advanced disease.

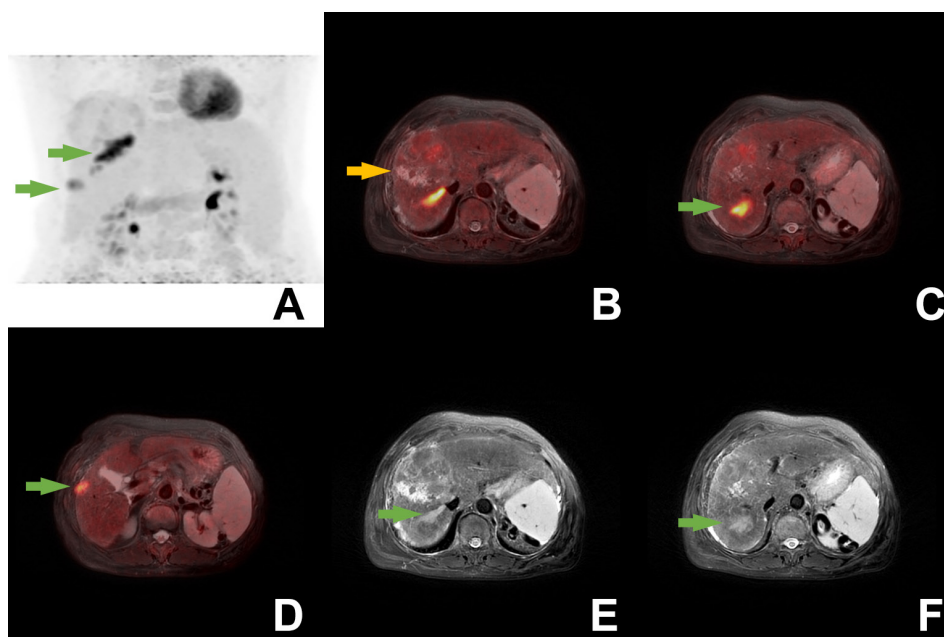


Figure 2. After 9 months of sorafenib treatment AFP levels were measured as low as 801 ng/mL. Post-treatment integrated ^{18}F -FDG PET/MRI revealed that diffuse infiltrating lesions had largely regressed. A few ^{18}F -FDG-avid lesions (green arrows) with maximum SUV_{max} : 10.9 including tumor thrombosis in right hepatic vein, could be visualized in MIP (A), axial T2-weighted MRI (E, F), axial PET/MRI fusion (B, C, D) images. There was no significant difference in MRI findings of large mass as it had a minimal decrease in diameter to 8 cm and is still mildly ^{18}F -FDG-avid (B-orange arrow).

HCC is one of the most prevalent cancers in the world (1,2). In advanced HCC cases treatment choices can be limited to systemic treatments such as tyrosine-kinase receptor inhibitors, vascular endothelial growth factor inhibitors and immunotherapy agents (3,4,5). As one of the most commonly used tyrosine-kinase inhibitors, sorafenib can increase overall survival in HCC patients (6). It has been shown that pretreatment ^{18}F -FDG PET/CT parameters have a prognostic value in HCC patients treated with sorafenib but intensity of ^{18}F -FDG uptake may not predict response to sorafenib treatment (7,8). In this case the lesions previously undetected in CT were demonstrated with both components of PET/MRI. Additionally, ^{18}F -FDG PET revealed different characteristics of these two pathologies, one being solitary non-FDG avid mass, other being intensely FDG-avid infiltrating lesions. Furthermore, more ^{18}F -FDG avid infiltrating lesions had a marked response to sorafenib while the other large solid mass was merely exhibiting stable disease. An effective response to sorafenib is rare, and in this case both PET and MRI revealed dramatic response of infiltrating lesions to treatment, consistent with clinical findings. In conclusion, PET can reveal metabolic characteristics of HCC lesions and usage of high soft tissue contrast of MRI can help identify corresponding lesions in liver. This could make the usage of PET/MRI valuable for diagnosis, staging and as demonstrated above evaluation of response to treatment.

Ethics

Informed Consent: Written informed consent was obtained from the patient.

Authorship Contributions

Surgical and Medical Practices: E.Ö., B.D., D.K.Ö., Y.Ü., N.Ö.K., Concept: E.Ö., B.D., Data Collection or Processing:

E.Ö., B.D., D.K.Ö., Y.Ü., N.Ö.K., Analysis or Interpretation: E.Ö., B.D., D.K.Ö., N.Ö.K., Literature Search: E.Ö., B.D., Writing: E.Ö., B.D.

Conflict of Interest: No conflicts of interest were declared by the authors.

Financial Disclosure: The authors declare that this study has received no financial support.

References

1. Sung H, Ferlay J, Siegel RL, Laversanne M, Soerjomataram I, Jemal A, Bray F. Global Cancer Statistics 2020: GLOBOCAN Estimates of Incidence and Mortality Worldwide for 36 Cancers in 185 Countries. *CA Cancer J Clin* 2021;71:209-249.
2. El-Serag HB, Mason AC. Rising incidence of hepatocellular carcinoma in the United States. *N Engl J Med* 1999;340:745-750.
3. Reig M, Forner A, Rimola J, Ferrer-Fàbrega J, Burrel M, Garcia-Criado Á, Kelley RK, Galle PR, Mazzaferro V, Salem R, Sangro B, Singal AG, Vogel A, Fuster J, Ayuso C, Bruix J. BCLC strategy for prognosis prediction and treatment recommendation: The 2022 update. *J Hepatol* 2022;76:681-693.
4. European Association For The Study Of The Liver; European Organisation For Research And Treatment Of Cancer. EASL-EORTC clinical practice guidelines: management of hepatocellular carcinoma. *J Hepatol* 2012;56:908-943.
5. Forner A, Reig M, Bruix J. Hepatocellular carcinoma. *Lancet* 2018;391:1301-1314.
6. Fan G, Wei X, Xu X. Is the era of sorafenib over? A review of the literature. *Ther Adv Med Oncol* 2020;12:1758835920927602.
7. Sung PS, Park HL, Yang K, Hwang S, Song MJ, Jang JW, Choi JY, Yoon SK, Yoo IR, Bae SH. ^{18}F -fluorodeoxyglucose uptake of hepatocellular carcinoma as a prognostic predictor in patients with sorafenib treatment. *Eur J Nucl Med Mol Imaging* 2018;45:384-391.
8. Lee JH, Park JY, Kim DY, Ahn SH, Han KH, Seo HJ, Lee JD, Choi HJ. Prognostic value of ^{18}F -FDG PET for hepatocellular carcinoma patients treated with sorafenib. *Liver Int* 2011;31:1144-1149.