



Late ⁶⁸Ga PSMA-positive Pancreatic Metastasis From Renal Cell Carcinoma in a Patient with Metastatic Prostate Cancer: A Mission Impossible

Metastatik Prostat Kanseri Bir Hastada Renal Hücreli Karsinomdan Geç ⁶⁸Ga PSMA-pozitif Pankreas Metastazı: İmkansız Bir Görev

✉ Gabriela Mateva¹, ✉ Nikolina Novoselska¹, ✉ Assen Dudov², ✉ Marina Garcheva-Tsacheva¹, ✉ Pavel Bochev¹

¹Acibadem City Clinic UMBAL Mladost Hospital, Department of Nuclear Medicine, Sofia, Bulgaria

²Acibadem City Clinic UMBAL Mladost Hospital, Department of Medical Oncology, Sofia, Bulgaria

Abstract

We present the case of a patient with newly diagnosed high-risk prostate cancer. The patient underwent nephrectomy for renal cell carcinoma (RCC) in 2009. The prostate-specific membrane antigen (PSMA) scan revealed a primary tumor with seminal vessel involvement, PSMA-positive regional lymph nodes, several nodular lung lesions with mild PSMA uptake, PSMA-positive mediastinal lymph nodes, and a PSMA-positive mass in the pancreatic head. Ultrasound-guided biopsy was performed for the pancreatic lesions revealing metastasis from a RCC. Simultaneous treatment for prostate cancer and metastatic RCC was initiated. To separate metastatic sites for both primaries, we attempted to use fluorodeoxyglucose positron emission tomography/computed tomography, which was moderately positive for the pancreatic mass but not for the other locations. RCC is a ⁶⁸Ga PSMA-positive tumor; the synchronous combination of RCC with prostate cancer can be confusing and requires more complex clinical interpretation.

Keywords: PSMA, FDG, PET/CT, prostate cancer, RCC, pancreatic metastasis

Öz

Bu olgu sunumunda yeni tanı almış yüksek riskli prostat kanseri olan bir hastayı sunuyoruz. Hastaya 2009 yılında renal hücreli karsinom (RHK) nedeniyle nefrektomi uygulandı. Prostat spesifik membran antijeni (PSMA) taramasında seminal vezikül tutulumu olan primer bir tümör, PSMA pozitif bölgesel lenf nodları, hafif PSMA tutulumu olan birkaç nodüler akciğer lezyonu, PSMA-pozitif mediastinal lenf nodları ve pankreas başında PSMA pozitif kitle saptandı. Pankreas lezyonları için ultrason eşliğinde biyopsi yapıldı ve bu lezyonların RHK metastazı olduğunu ortaya çıkardı. Prostat kanseri ve metastatik RHK'nin eşzamanlı tedavisine başlandı. Her iki primer için metastatik bölgeleri ayırmak amacıyla, florodeoksiglukoz pozitron emisyon tomografisi/bilgisayarlı tomografiyi kullanmayı denedik; bu, pankreas kitlesi için orta derecede pozitif, ancak diğer lokasyonlar için pozitif değildi. RHK, ⁶⁸Ga PSMA pozitif bir tümördür; RHK'nin prostat kanseri ile eşzamanlı kombinasyonu kafa karıştırıcı olabilir ve daha karmaşık klinik yorumlama gerektirir.

Anahtar kelimeler: PSMA, FDG, PET/BT, prostat kanseri, RHK, pankreas metastazı

Address for Correspondence: Gabriela Mateva MD, Acibadem City Clinic UMBAL Mladost Hospital, Department of Nuclear Medicine, Sofia, Bulgaria

Phone: +359894680648 **E-mail:** gabriela.mateva@abv.bg ORCID ID: orcid.org/0000-0001-8834-995X

Received: 28.08.2023 **Accepted:** 07.12.2023 **Epub:** 19.02.2024



Copyright© 2024 The Author. Published by Galenos Publishing House on behalf of the Turkish Society of Nuclear Medicine.
This is an open access article under the Creative Commons Attribution-NonCommercial-NoDerivatives 4.0 (CC BY-NC-ND) International License.

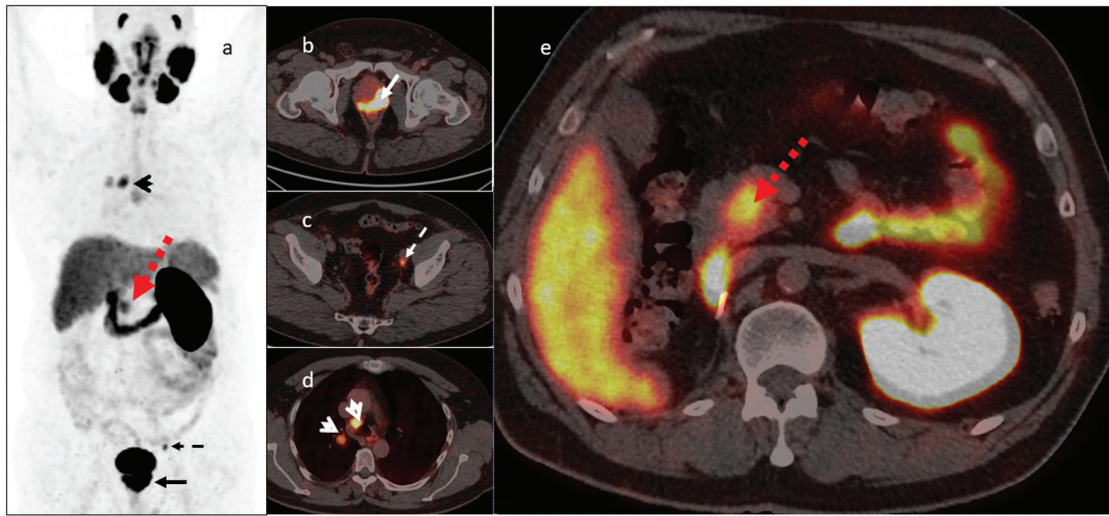


Figure 1. ⁶⁸Ga prostate-specific membrane antigen (PSMA) scan performed for staging of prostate cancer [Gleason score of 7 (4+3), grade group 3, initial prostate-specific antigen (PSA) 206 ng/mL] [a- maximum intensity projection (MIP) image], revealing a highly positive primary prostate tumor (b, arrow-axial hybrid image) with parailiac lymph node metastasis (c, dashed arrow-axial hybrid image), a PSMA-positive paratracheal lymph node, and a round, well-shaped lung metastasis (d, open arrow-axial hybrid image). PSMA-positive lesion in the pancreatic head (e, red arrow-axial hybrid image). The patient underwent nephrectomy for renal cell carcinoma (RCC) in 2009 and was considered to be in remission. Knowing that the pancreas is a possible location for late RCC metastasis and can be PSMA-positive (1,2), we recommended an ultrasound-guided biopsy for the pancreatic lesion, which proved infiltration by a typical clear cell renal carcinoma, PAX 8 and GATA3 positive, although RCC negative on immunohistochemistry. Simultaneous treatment for prostate cancer and metastatic RCC was initiated as follows: hormone therapy maximal androgen blockade for prostate cancer and bevacizumab/interferon, later changed to pazopanib for RCC.

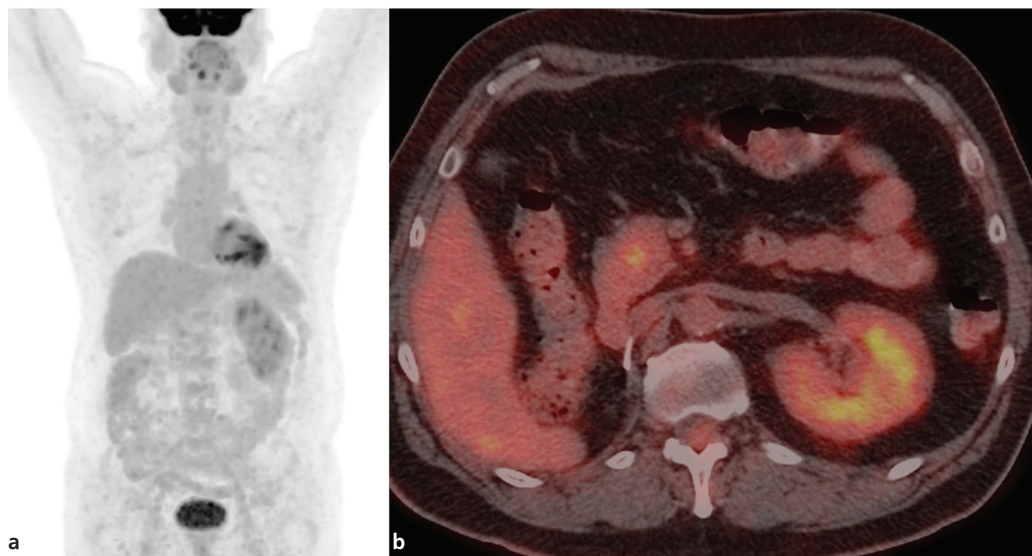


Figure 2. Fluorodeoxyglucose (FDG) positron emission tomography scan: pancreatic lesion is faintly FDG positive. The other lesions did not show substantial FDG uptake (should be borne on mind that the patient is under treatment at the time of the FDG scan). a. ¹⁸F-FDG MIP image; b. ¹⁸F-FDG axial hybrid imaging faint FDG uptake in the pancreatic lesion. To separate metastatic sites for both primaries, we attempted to use FDG PET/computed tomography (CT) (Figure 2) as a discriminator, as proposed in the literature (3). The scan was obtained after starting treatment for both and at PSA levels of 3.24 ng/mL. FDG was moderately positive for the pancreatic mass but not for the other locations (lung nodules were small volume) (Figure 2). On a size basis, there was no change in the pancreatic mass, but there was a reduction in the lung, mediastinal, and primary prostate sites, which additionally confused the interpretation. However, as a final decision, the patient had partial response for prostate cancer and non-progression (partial response or stable disease) for RCC and remained on the same treatment. This actually shows the inability of separating metastatic locations for all imaging modalities used (⁶⁸Ga PSMA, FDG, and CT) and the need for an individual approach and more complex clinical interpretation of the case.

Ethics

Informed Consent: The patient has consented to the use of his medical record for scientific purposes.

Authorship Contributions

Surgical and Medical Practices: A.D., P.B., Concept: P.B., Design: P.B., Data Collection or Processing: G.M., N.N., P.B., Analysis or Interpretation: G.M., N.N., M.G.-T., P.B., Literature Search: P.B., Writing: G.M., P.B.

Conflict of Interest: No conflicts of interest were declared by the authors.

Financial Disclosure: The authors declare that this study has received no financial support.

References

1. Katsourakis A, Noutsios G, Hadjis I, Alatsakis M, Chatzitheoklitos E. Late solitary pancreatic metastasis from renal cell carcinoma: a case report. *Case Rep Med* 2012;2012:464808.
2. Demirci E, Ocak M, Kabasakal L, Decristoforo C, Talat Z, Halaç M, Kanmaz B. (68)Ga-PSMA PET/CT imaging of metastatic clear cell renal cell carcinoma. *Eur J Nucl Med Mol Imaging* 2014;41:1461-1462.
3. Tariq A, Kwok M, Pearce A, Rhee H, Kyle S, Marsh P, Raveenthiran S, Wong D, McBean R, Westera J, Dungleison N, Esler R, Navaratnam A, Yaxley JW, Thomas P, Pattison DA, Roberts MJ. The role of dual tracer PSMA and FDG PET/CT in renal cell carcinoma (RCC) compared to conventional imaging: A multi-institutional case series with intra-individual comparison. *Urol Oncol* 2022;40:66.e1-66.e9.