



Diagnosis and Evaluation of Treatment Response in Relapsing Polychondritis Using ¹⁸F-FDG PET/CT

Tekrarlayan Polikondrit Tanısında ve Tedavi Yanıt Değerlendirmesinde ¹⁸F-FDG PET/BT

Caner Civan¹, Emine Göknur Işık¹, Duygu Has Şimşek¹, Mustafa Altınkaynak², Serkan Kuyumcu¹

¹Istanbul University, Istanbul Faculty of Medicine, Department of Nuclear Medicine, Istanbul, Türkiye

²Istanbul University, Istanbul Faculty of Medicine, Department of Internal Medicine, Istanbul, Türkiye

Abstract

A 58-year-old man presenting with dyspnea, weight loss, and night sweating underwent ¹⁸F-fluorodeoxyglucose positron emission tomography/computed tomography (¹⁸F-FDG PET/CT) because of a suspicion of malignancy. ¹⁸F-FDG PET/CT demonstrated mild to moderate uptake on nasal, cricoid, and tracheobronchial tree cartilages and costovertebral junctions. The diagnosis was relapsing polychondritis, which is a rare multisystem disease characterized by inflammation of cartilage. In addition, subsequent ¹⁸F-FDG PET/CT after treatment showed complete metabolic response.

Keywords: Relapsing polychondritis, ¹⁸F-FDG, PET/CT

Öz

Elli sekiz yaşında kadın hastaya nefes darlığı, kilo kaybı ve gece terlemesi şikayetleri ile malignite şüphesi nedeniyle ¹⁸F-fluorodeoksiglukoz pozitron emisyon tomografisi/bilgisayarlı tomografi (¹⁸F-FDG PET/BT) çalışması yapıldı. ¹⁸F-FDG PET/BT'de nazal, krikoid, trakeobronşiyal ağaç kıkırdaklarında ve kostovertebral bileşelerde ve hafif orta düzeyde tutulumlar gözlemlendi. Hastanın tanısı nadir görülen, multisistemik bir hastalık olan ve kıkırdakların enflamasyonu ile karakterize tekrarlayan polikondrit ile uyumlu idi. Tedavi sonrası yapılan ¹⁸F-FDG PET/BT çalışmasında tam metabolik yanıt görülmekte idi.

Anahtar kelimeler: Tekrarlayan polikondrit, ¹⁸F-FDG, PET/BT

Address for Correspondence: Caner Civan MD, Istanbul University, Istanbul Faculty of Medicine, Department of Nuclear Medicine, Istanbul, Türkiye

Phone: +90 535 559 39 25 **E-mail:** dr.canercivan@gmail.com ORCID ID: orcid.org/0000-0003-4745-3501

Received: 11.08.2023 **Accepted:** 26.11.2023 **Epub:** 19.02.2024



Copyright© 2024 The Author. Published by Galenos Publishing House on behalf of the Turkish Society of Nuclear Medicine. This is an open access article under the Creative Commons Attribution-NonCommercial-NoDerivatives 4.0 (CC BY-NC-ND) International License.

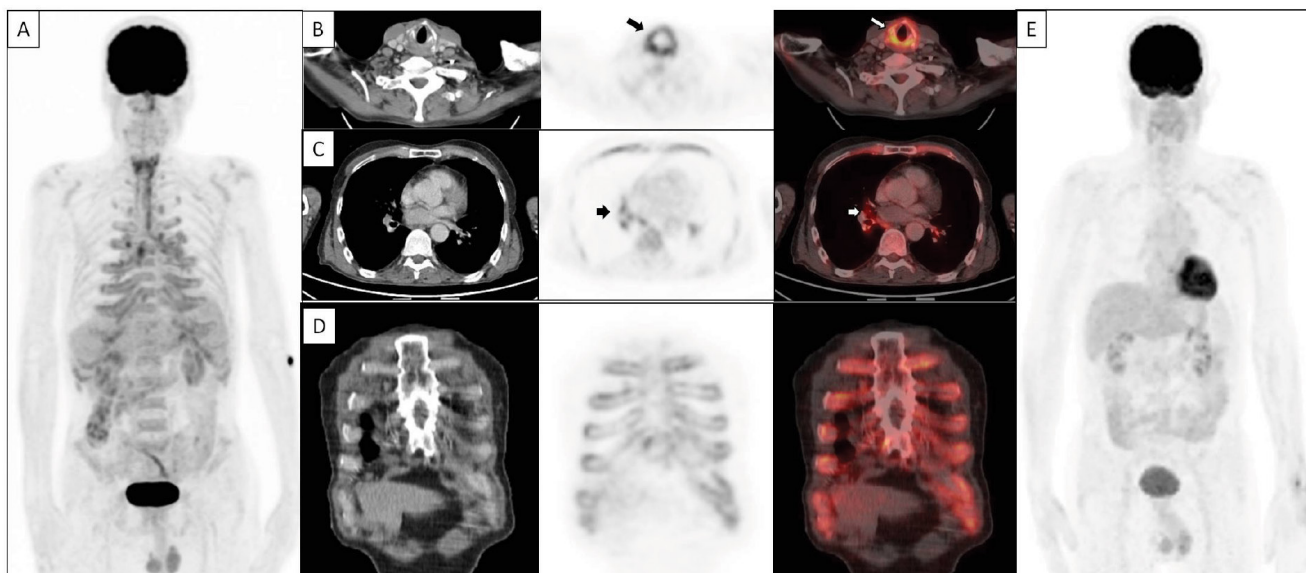


Figure 1. A 58-year-old man with a history of granulomatosis with polyangiitis presented with shortness of breath, hoarseness, myalgia, arthralgia, and weight loss of 10 kg within two months. Laboratory findings were as follows: C-reactive protein (CRP), 144 mg/L, erythrocyte sedimentation rate (ESR): 93, white blood cell counts, 12,000; and hemoglobin level, 10 g/dL. Due to anemia and age, the patient underwent gastroscopy and colonoscopy, which revealed esophagitis and gastritis. Because of suspected malignancy, the patient underwent ¹⁸F-fluorodeoxyglucose positron emission tomography/computed tomography (¹⁸F-FDG PET/CT) [A: maximum intensity projection, (MIP)], which showed increased FDG uptake in multiple cartilage joints. Transaxial images demonstrated increased uptake on the cricoid cartilage of the larynx [B: CT, PET and fused PET/CT images, arrow, maximum standardized uptake value (SUV_{max}): 6.8] and tracheobronchial cartilages (C: CT, PET and fused PET/CT images, arrow, SUV_{max}: 5.4). Coronal images of the thorax show (D: CT, PET and fused PET/CT images) increased FDG uptake at costochondral junctions (SUV_{max}: 3.4). Considering these findings, which were chondritis of the nasal cartilage and respiratory tract with a combination of clinical features, the diagnosis was confirmed as relapsing polychondritis (RPC). The patient received treatment with corticosteroids and methotrexate as anti-inflammatory agents. Subsequently, the patient underwent ¹⁸F-FDG PET/CT (E: MIP) for response evaluation, which showed complete metabolic response and acute phase reactants within normal range (CRP: 1.58 mg/L, ESR: 8, white blood cell counts: 7,500). RPC is an orphan disease with an estimated incidence rate of 3.5 in 1 million people (1). RPC, which is associated with progressive autoimmune disorder of cartilage, presents with heterogeneous signs and symptoms in compliance with involvement of structures (2). Because of non-specific symptoms in the early stage of the disease, diagnosis has been delayed in most of the cases (2). Indeed, laboratory findings, part of the diagnostic work-up of RPC, were consistent with inflammation but non-specific to RPC (3). Based on the clinical features, various diagnostic criteria were proposed, including chondritis, which mainly involved auricular, nasal, and laryngotracheobronchial diseases, and arthropathy, which was mainly acute, asymmetric polyarthritis, or oligoarthritis (4). In the last decade, the utility of ¹⁸F-FDG PET/CT has been proven in not only oncological purposes but also in non-oncological settings, including inflammatory disorders (5,6). The clinical importance of ¹⁸F-FDG PET/CT in RPC for early diagnosis, targeted biopsy site, extent of disease, and treatment response evaluation has been shown in limited studies (7,8). This case highlights the importance of recognizing the typical distribution patterns of RPC on ¹⁸F-FDG PET/CT for accurate diagnosis. Furthermore, ¹⁸F-FDG PET/CT may play a role in evaluating the treatment response in RPC.

Ethics

Informed Consent: Patient consent was obtained.

Authorship Contributions

Surgical and Medical Practices: C.C., E.G.I., D.H.Ş., M.A., S.K., Concept: C.C., E.G.I., D.H.Ş., Design: C.C., E.G.I., D.H.Ş., Data Collection or Processing: C.C., M.A., Analysis or Interpretation: C.C., E.G.I., D.H.Ş., S.K., Literature Search: C.C., D.H.Ş., Writing: C.C., E.G.I., D.H.Ş., M.A., S.K.

Conflict of Interest: No conflicts of interest were declared by the authors.

Financial Disclosure: The authors declare that this study has received no financial support.

References

1. Luthra HS. Relapsing polychondritis. Primer on the rheumatic diseases, Springer 2008;451-454.
2. Longo L, Greco A, Rea A, Lo Vasco VR, De Virgilio A, De Vincentiis M. Relapsing polychondritis: A clinical update. *Autoimmun Rev* 2016;15:539-543.
3. Kingdon J, Roscamp J, Sangle S, D’Cruz D. Relapsing polychondritis: a clinical review for rheumatologists. *Rheumatology (Oxford)* 2018;57:1525-1532.
4. Borgia F, Giuffrida R, Guarneri F, Cannavò SP. Relapsing polychondritis: an updated review. *Biomedicines* 2018;6:84.
5. Zhuang H, Codreanu I. Growing applications of FDG PET-CT imaging in non-oncologic conditions. *J Biomed Res* 2015;29:189-202.
6. Pijl JP, Nienhuis PH, Kwee TC, Glaudemans AWJM, Slart RHJA, Gormsen LC. Limitations and pitfalls of FDG-PET/CT in infection and inflammation. *Semin Nucl Med* 2021;51:633-645.
7. Kubota K, Yamashita H, Mimori A. Clinical value of FDG-PET/CT for the evaluation of rheumatic Diseases: rheumatoid arthritis, polymyalgia rheumatica, and relapsing polychondritis. *Semin Nucl Med* 2017;47:408-424.
8. Kwok SH, Choi F. Relapsing polychondritis: the oto-rhino-tracheobronchial triad on 18 F-FDG PET/CT. *Clin Nucl Med* 2023;48:699-701.