



# An Uncommon Case of Pediatric Nasopharyngeal Carcinoma with Bone Metastases and Enchondromas Evaluated Using <sup>18</sup>F-FDG PET/CT

<sup>18</sup>F-FDG PET/BT Taraması ile Değerlendirilen, Kemik Metastazları ve Enkondromları Olan Nadir Bir Pediatrik Nazofaringeal Karsinom Olgusu

✉ Natale Quartuccio<sup>1\*</sup>, ✉ Salvatore Ialuna<sup>1\*</sup>, ✉ Salvatore Poma<sup>2</sup>, ✉ Vincenzo Luca Lentini<sup>3</sup>, ✉ Alessandro Pitruzzella<sup>4</sup>, ✉ Giuseppe Mario Galfano<sup>2</sup>, ✉ Antonino Maria Moreci<sup>1</sup>, ✉ Domenico Michele Modica<sup>2,4</sup>

<sup>1</sup>Ospedali Riuniti Villa Sofia-Cervello, Department of Nuclear Medicine, Palermo, Italy

<sup>2</sup>Ospedali Riuniti Villa Sofia-Cervello, U.O.C. Otolaryngology, Palermo, Italy

<sup>3</sup>Ospedali Riuniti Villa Sofia-Cervello, Unit of Pathology, Palermo, Italy

<sup>4</sup>University of Palermo, Neurosciences and Advanced Diagnostics (BIND), Institute of Human Anatomy and Histology, Department of Biomedicine, Palermo, Italy

## Abstract

Nowadays, the utility of positron emission tomography/computed tomography (PET/CT) is well established in nasopharyngeal carcinoma (NPC). The incidence of NPC in the West population, especially in children, is very low. We present the first Italian case of a pediatric patient with NPC followed up with <sup>18</sup>F-fluorodeoxyglucose (<sup>18</sup>F-FDG) PET/CT scan in addition to the standard follow-up imaging methods, including CT and magnetic resonance imaging. The <sup>18</sup>F-FDG PET/CT scan was helpful in discriminating between metastatic and benign osseous lesions, thereby helping clinicians to determine the most appropriate therapeutic regimen. These findings support the clinical utility of <sup>18</sup>F-FDG PET/CT in the diagnostic work-up of pediatric patients with NPC.

**Keywords:** Positron emission tomography, <sup>18</sup>F-fluorodeoxyglucose, nasopharyngeal carcinoma, pediatrics

## Öz

Günümüzde nazofaringeal karsinomda (NFK) pozitron emisyon tomografisi/bilgisayarlı tomografinin (PET/BT) kullanımı iyice yerleşmiştir. Batı popülasyonunda, özellikle de pediatrik yaşta NFK'nin görülme sıklığı çok düşüktür. BT ve manyetik rezonans görüntüleme dahil olmak üzere standart takip görüntüleme yöntemlerine ek olarak <sup>18</sup>F-florodeoksiglukoz (<sup>18</sup>F-FDG) PET/BT taraması yoluyla takip edilen NFK'li ilk İtalyan pediatrik hastayı sunuyoruz. <sup>18</sup>F-FDG PET/BT taraması, metastatik ve iyi huylu kemik lezyonları arasında ayırım yapılmasında ve klinisyenlerin en uygun terapötik rejimi belirlemesine yardımcı olmuştur. Bu bulgular, NFK'li pediatrik hastaların tanılma çalışmalarında <sup>18</sup>F-FDG PET/BT taramasının klinik faydasını desteklemektedir.

**Anahtar kelimeler:** Pozitron emisyon tomografisi, <sup>18</sup>F-florodeoksiglukoz, nazofaringeal karsinom, pediatri

\*These authors contributed equally to this work.

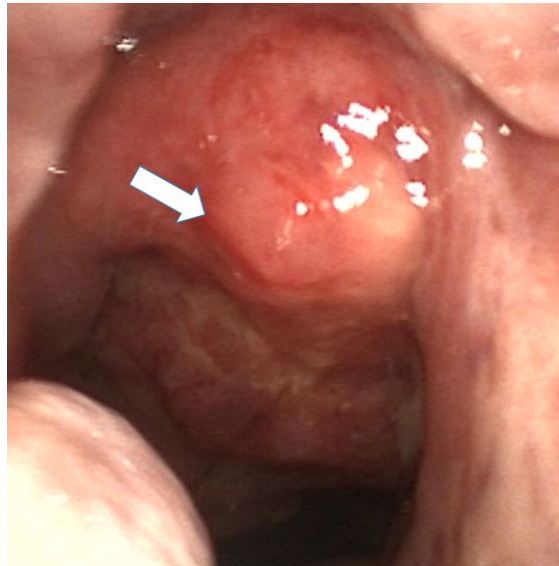
**Address for Correspondence:** Natale Quartuccio MD, Ospedali Riuniti Villa Sofia-Cervello, Department of Nuclear Medicine, Palermo, Italy

**Phone:** +390917804242 **E-mail:** n.quartuccio@villasofia.it ORCID ID: orcid.org/0000-0001-9845-1384

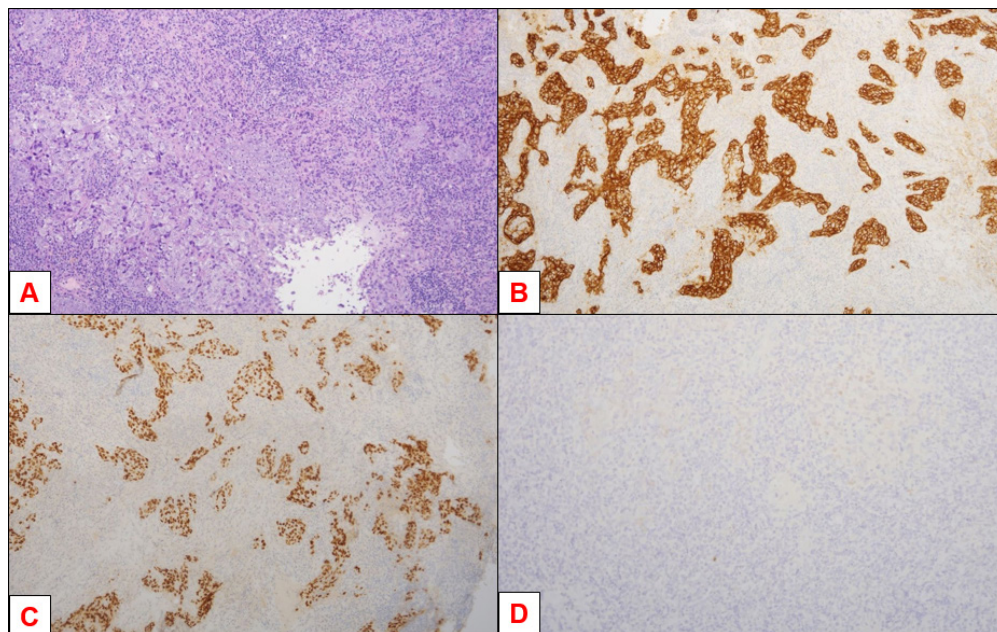
**Received:** 20.08.2023 **Accepted:** 27.12.2023 **Epub:** 19.02.2024



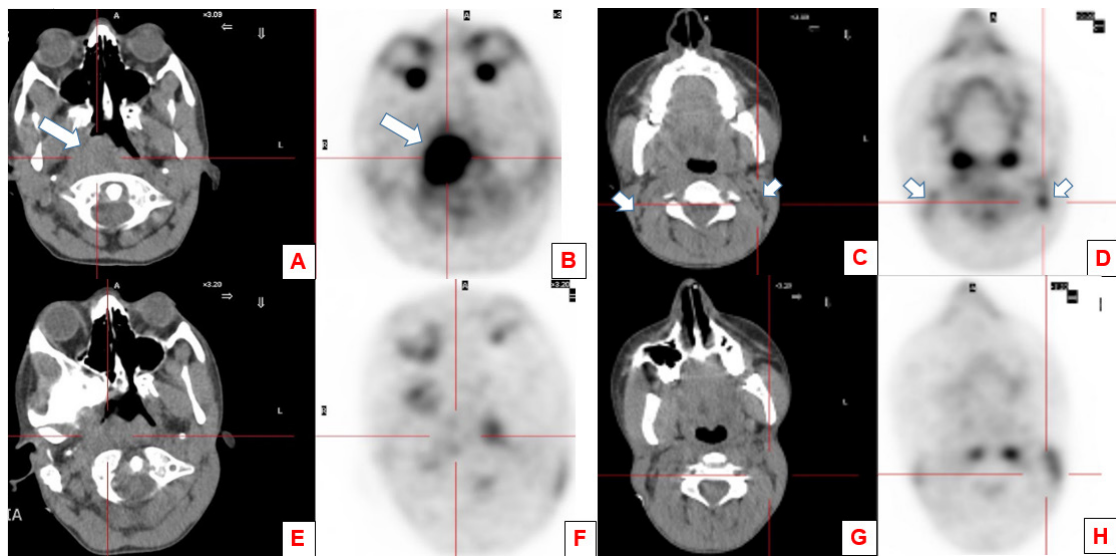
Copyright© 2024 The Author. Published by Galenos Publishing House on behalf of the Turkish Society of Nuclear Medicine. This is an open access article under the Creative Commons Attribution-NonCommercial-NoDerivatives 4.0 (CC BY-NC-ND) International License.



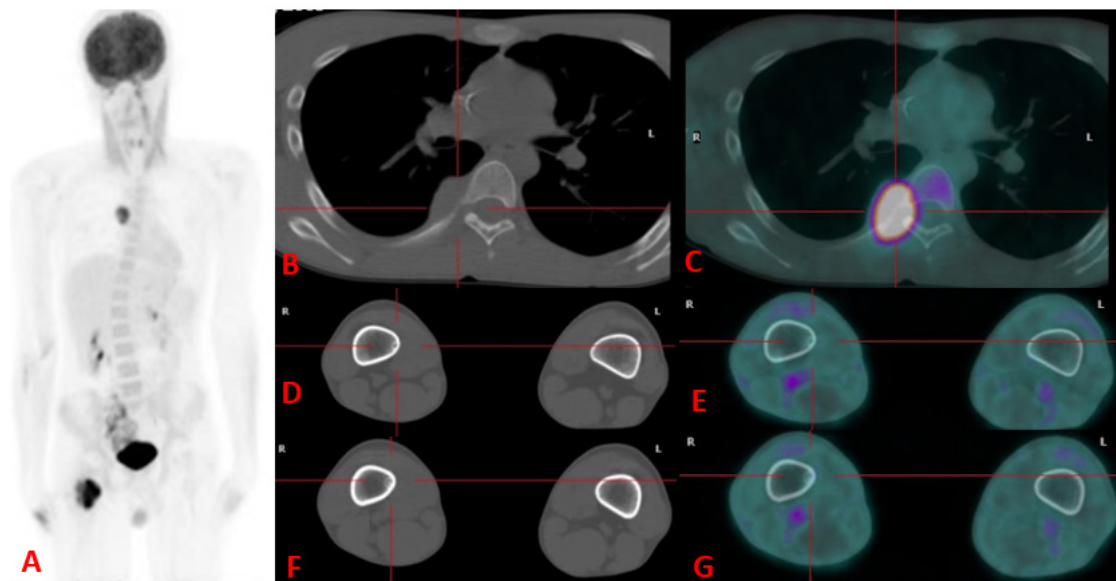
**Figure 1.** A 15-year-old adolescent was directed to our care because of recent occurrences of bloody nasal discharge, nasal blockage, and pain in the right ear. These symptoms had appeared approximately a month earlier. A video examination of the nose and throat revealed a lesion (indicated by a white arrow) on the right side of the nasopharynx, which was subsequently subjected to a biopsy procedure performed under general anesthesia.



**Figure 2.** The tissue sample was sent for pathology. Histological examination (A-D) of the lesion identified a non-keratinizing undifferentiated carcinoma [classified as World Health Organization (WHO) type 3] located in the nasopharynx/rhinopharynx revealed non-keratinizing undifferentiated carcinoma (WHO type 3) of the nasopharynx. A: Hematoxylin and eosin staining (at 10x magnification) demonstrates lymphoid tissue mixed to an undifferentiated, atypical neoplastic cell population. B: At 10x magnification, immunohistochemical staining revealed positivity for an antibody targeting cytokeratin (Monoclonal Mouse Anti-Human Cytokeratin, Clone MNF116, Isotype: IgG1, kappa, 1:300; Dako Deutschland GmbH, Hamburg, Germany). C: The immunohistochemical staining at 10x magnification demonstrated p40 immunostaining positivity, supporting the diagnosis of squamous cell differentiation. D: At 20x magnification, immunohistochemical staining demonstrated Epstein-Barr virus (EBV)-encoded RNA positivity, indicating the EBV viral genome within neoplastic cells.



**Figure 3.** In addition to contrast-enhanced (CE) computed tomography (CT) and head and neck magnetic resonance imaging (MRI), the patient underwent a  $^{18}\text{F}$ -fluorodeoxyglucose positron emission tomography/CT ( $^{18}\text{F}$ -FDG PET/CT) scan for local staging of nasopharyngeal carcinoma (NPC). PET/CT scans were acquired on an integrated PET/CT scanner (Discovery ST, General Electric Medical System, Milwaukee, WI, USA). The lesion identified on the CT component (white arrow, A) of the PET/CT scanner demonstrated anterior extension toward the septum and involvement of the retropharyngeal and prevertebral regions. PET/CT scan demonstrated increased  $^{18}\text{F}$ -FDG uptake [maximum standardized uptake value ( $\text{SUV}_{\text{max}}$ ): 14.3] (white arrow, B) within a solid right-sided mass. The mass had a maximum diameter of 47 mm on the axial plane and was located in the right vault wall of the nasopharynx. In addition, bilateral  $^{18}\text{F}$ -FDG-avid ( $\text{SUV}_{\text{max}}$ : 7.5) superior jugular lymph nodes (white arrows, C, D), suspected for metastatic lesions, were noted. The child underwent three courses of induction chemotherapy (cisplatin/5-fluorouracil) and a further PET/CT scan, which demonstrated decreased size and uptake of the nasopharyngeal mass (E, F) and lymph nodes (G, H). Subsequently, the patient underwent radiotherapy (64.8 Gy) with concomitant chemotherapy.



**Figure 4.** Two months later, the patient experienced right leg pain, prompting the referring clinician to order a leg CE MRI. MRI revealed a pathological tissue with a likely heteroplasic appearance, displaying prominent contrast enhancement in the intertrochanteric and lesser trochanter regions of the right femur. This tissue did not involve the cortical bone but infiltrated the muscular plane adjacent to the lesion in the medial region of the thigh. Additionally, two further doubtful well-defined lesions, measuring 4 and 2 cm, were observed in the distal diaphysis of the right femur.

An additional <sup>18</sup>F-FDG PET/CT was conducted, highlighting increased uptake in the intertrochanteric and lesser trochanter lesions, whereas the other two distal diaphysis lesions showed no significant <sup>18</sup>F-FDG uptake. Furthermore, a further hypermetabolic lesion (SUV<sub>max</sub>: 8.4) was noted in the right-sided sixth costovertebral joint. On the left box (A) maximum intensity projection image showing <sup>18</sup>F-FDG-avid metastases in the intertrochanteric and lesser trochanter regions of the right femur and in the sixth right-sided rib, with corresponding CT and fused PET/CT images in boxes B and C, respectively. An additional <sup>18</sup>F-FDG-avid lesion involving the great and lesser trochanter of the right femur was observed, whereas tiny lesions seen on CT images were confirmed to be enchondromas with no significant FDG uptake (D, E, F, G).

Based on the PET/CT findings, chemotherapy with gemcitabine and oxaliplatin was administered, and radiation therapy (30 Gy) was delivered to the proximal region of the right femur. After 5 months, post-therapy PET/CT revealed the disappearance of the hypermetabolic lesions in keeping with a complete metabolic response to therapy. Since then, the boy has been followed up by two further <sup>18</sup>F-FDG PET/CT scans with no evidence of disease recurrence. The lesions in the distal diaphysis of the right femur were followed up by MRI and after 1 year remained unchanged, in keeping with enchondromas, according to the radiologist.

The incidence of NPC in the Western countries is low (especially in the pediatric age) compared with that in South-Eastern Asia (one vs. 8 per 100,000 person per year) (1,2). Although most nasopharyngeal lesions in the pediatric population are benign, the possibility of NPC should be considered when symptoms last long (3). Current imaging methods used to assess NPC at diagnosis and follow-up include CT, MRI, and bone scan. To the best of our knowledge, this is the first pediatric case of NPC evaluated by <sup>18</sup>F-FDG PET/CT reported in Italy. <sup>18</sup>F-FDG PET/CT emerged as an additional tool because of its metabolic information, helping characterize doubtful findings at conventional imaging (4). In our case, <sup>18</sup>F-FDG PET/CT played a crucial role in characterizing the enchondromas in the distal femur, as these well-defined lesions on the MRI scan demonstrated no significant uptake of <sup>18</sup>F-FDG, consistent with previous findings in the literature. Only three pediatric case reports (5,6,7) and one original study (4) including exclusively pediatric patients with NPC have been published in western countries so far. In that original

study, Cheuk et al. (4) proved in a group of 86 children that MRI is superior to <sup>18</sup>F-FDG PET/CT in the local staging and detection of local lymph node metastases. Nevertheless, <sup>18</sup>F-FDG PET/CT was useful to address the correct nature of ambiguous findings suspected for distant metastases and to estimate complete disease remission at 3-6 months after months, a timeline earlier than that achievable with MRI (4).

## Ethics

**Informed Consent:** Informed consent was obtained from all patients included in the study.

## Authorship Contributions

Surgical and Medical Practices: S.I., S.P., A.P., Concept: D.M.M., Design: S.P., Data Collection or Processing: V.L.L., A.M.M., Analysis or Interpretation: S.I., A.P., G.M.G., Literature Search: N.Q., Writing: N.Q., D.M.M.

**Conflict of Interest:** No conflicts of interest were declared by the authors.

**Financial Disclosure:** The authors declare that this study has received no financial support.

## References

- Gatta G. Epidemiological Aspects in Nasopharyngeal Cancer. In: Vermorken JB, Budach V, Leemans CR, Machiels J-P, Nicolai P, O'Sullivan B (eds.) *Critical Issues in Head and Neck Oncology*. Cham, Springer 2021;319-325.
- Boussen H, Bouaouina N, Mokni-Baizig N, Gamoudi A, Chouchane L, Benna F, Ladgham A. Les carcinomes du nasopharynx: donnée actuelles [Nasopharyngeal carcinoma. Recent data]. *Pathol Biol (Paris)* 2005;53:45-51.
- Ben-Ami T, Kontny U, Surun A, Brecht IB, Almaraz RL, Dragomir M, Pourtsidis A, Casanova M, Fresneau B, Bisogno G, Schneider DT, Reguerre Y, Bien E, Stachowicz-Stencel T, Österlundh G, Wygoda M, Janssens GO, Zsiros J, Jehanno N, Brisse HJ, Gandola L, Christiansen H, Claude L, Ferrari A, Rodriguez-Galindo C, Orbach D. Nasopharyngeal carcinoma in children and adolescents: The EXPERT/PARTNER diagnostic and therapeutic recommendations. *Pediatr Blood Cancer* 2021;68:e29018.
- Cheuk DK, Sabin ND, Hossain M, Wozniak A, Naik M, Rodriguez-Galindo C, Krasin MJ, Shulkin BL. PET/CT for staging and follow-up of pediatric nasopharyngeal carcinoma. *Eur J Nucl Med Mol Imaging* 2012;39:1097-1106.
- Stolten M, Moak S, Chauhan A, Warriar R. Facial pain in a child with attention deficit hyperactivity disorder. *Clin Pediatr (Phila)* 2016;55:196-198.
- Muzaffar R, Vacca F, Guo H, Mhapsekar R, Osman MM. Pediatric nasopharyngeal carcinoma as seen on <sup>18</sup>F-FDG PET/CT. *Front Oncol* 2019;9:110.
- Stokken J, Manz RM, Flagg A, Kate Gowans L, Anne S. Synchronous occurrence of nasopharyngeal carcinoma and Hodgkin lymphoma. *Int J Pediatr Otorhinolaryngol* 2014;78:154-156.