



# Unusual Soft Tissue Uptake of Tc-99m MDP in Radiation-induced Sarcoma: Diagnostic Conundrum

Radyasyona Baęlı Sarkomda Yumuşak Dokuda Beklenmedik Tc-99m MDP Tutulumu: Tanısal İkilem

Sharjeel Usmani<sup>1</sup>, Anjali Jain<sup>1</sup>, Khulood Al Riyami<sup>1</sup>, Zahida Niaz<sup>2</sup>, Subhash Kheruka<sup>1</sup>, Vipin V Jayakrishnan<sup>1</sup>

<sup>1</sup>Sultan Qaboos Comprehensive Cancer Care and Research Center, Department of Radiology and Nuclear Medicine, Muscat, Oman

<sup>2</sup>Sultan Qaboos Comprehensive Cancer Care and Research Center, Department of Pathology, Muscat, Oman

## Abstract

Tc-99m methylene diphosphonate (MDP) is a bone imaging agent used for skeletal staging, but it can also be localized in extrasosseous calcifying lesions. We report a case of an 84-year-old woman with breast carcinoma who underwent surgery followed by radiotherapy 10 years ago and now presented with a right axillary mass referred for Tc-99m MDP to exclude bone metastasis. Tc-99m MDP shows intense tracer uptake in the right thoracic region corresponding to the site of calcified soft tissue mass in the right lateral chest wall. Subsequent ultrasonography revealed an ill-defined lesion containing coarse calcifications. Biopsy showed radiation-induced sarcoma. Extra osseous Tc-99m MDP uptake may provide important diagnostic information that may alter patient management.

**Keywords:** Tc-99m MDP bone scan, extrasosseous uptake, radiation-induced sarcoma, breast cancer

## Öz

Tc-99m metilen difosfonat (MDP), iskelet evrelemesi için kullanılan bir kemik görüntüleme ajanıdır, ancak aynı zamanda kemik dışı kalsifiye lezyonlarda da lokalize edilebilir. Bu olgu sunumunda, sağ koltuk altı kitlesi ile başvuran ve kemik metastazını dışlamak için Tc-99m MDP'ye yönlendirilen, 10 yıl önce ameliyat olan ve ardından radyoterapi gören 84 yaşında meme karsinomlu bir kadın hastayı sunuyoruz. Tc-99m MDP, sağ yan göğüs duvarındaki kalsifiye yumuşak doku kitlesinin bulunduğu bölgeye karşılık gelen sağ torasik bölgede yoğun izleyici tutulumunu göstermektedir. Daha sonraki ultrasonografide kaba kalsifikasyonlar içeren, iyi tanımlanamayan bir lezyon saptanmıştır. Biyopsi radyasyonun neden olduğu sarkomu göstermiştir. Ekstra kemik Tc-99m MDP tutulumu, hasta yönetimini değiştirebilecek önemli tanısal bilgiler sağlayabilir.

**Anahtar kelimeler:** Tc-99m MDP kemik taraması, kemik dışı tutulum, radyasyona baęlı sarkom, meme kanseri

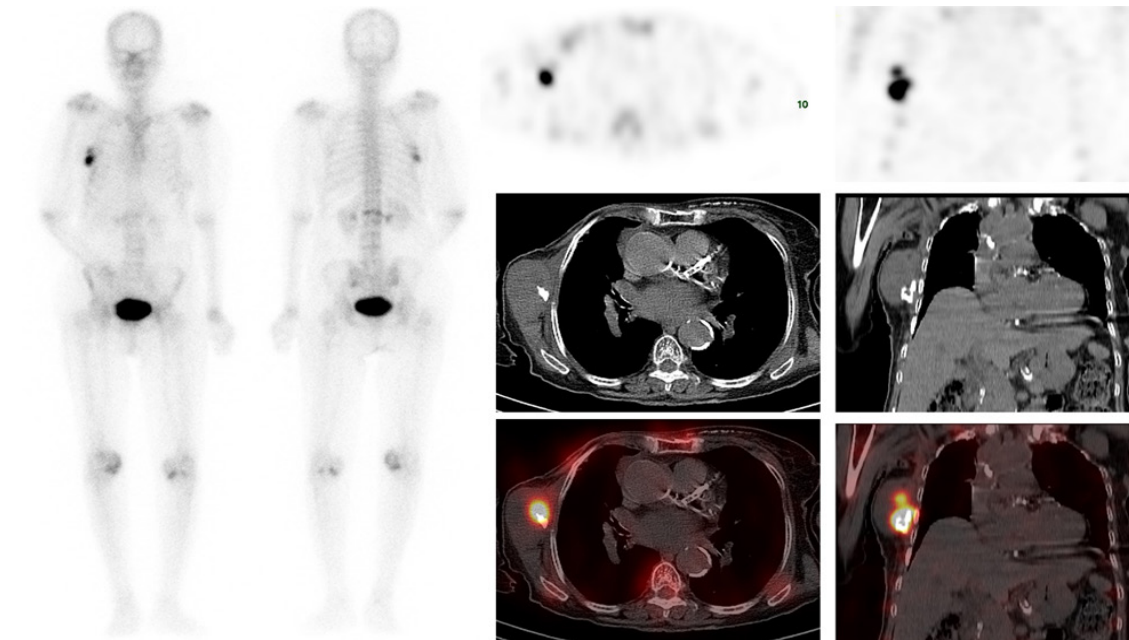
**Address for Correspondence:** Sharjeel Usmani MD, Sultan Qaboos Comprehensive Cancer Care and Research Center, Department of Radiology and Nuclear Medicine, Muscat, Oman

**Phone:** +96893219764 **E-mail:** dr\_shajji@yahoo.com **ORCID ID:** orcid.org/0000-0001-9274-7571

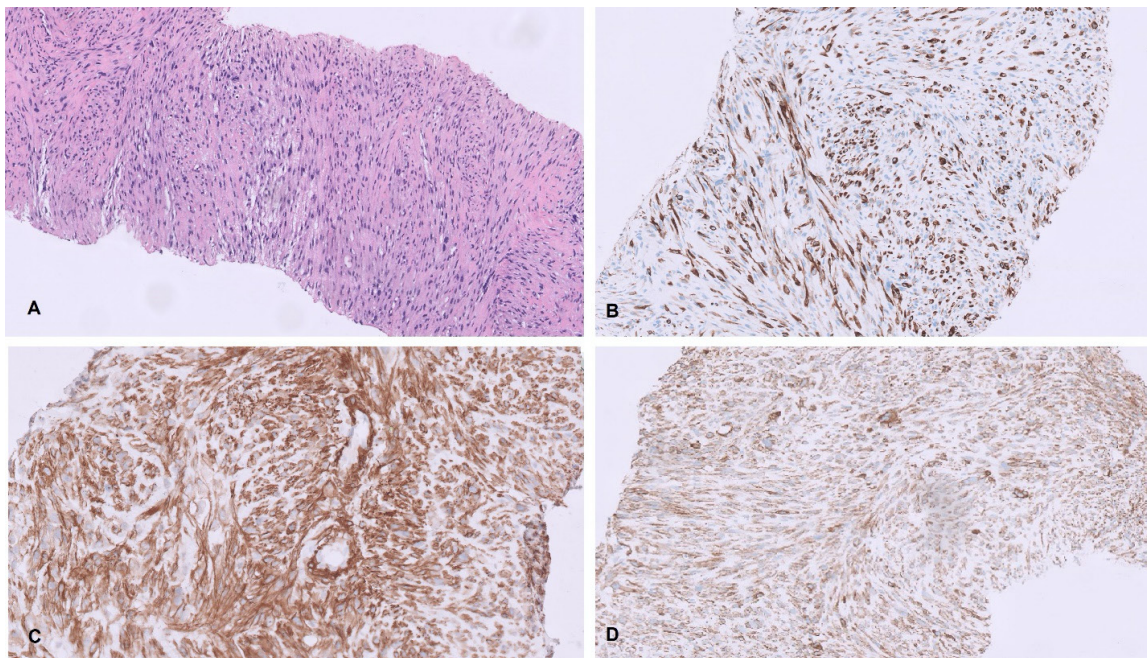
**Received:** 07.08.2023 **Accepted:** 05.11.2023 **Epub:** 19.02.2024



Copyright© 2024 The Author. Published by Galenos Publishing House on behalf of the Turkish Society of Nuclear Medicine. This is an open access article under the Creative Commons Attribution-NonCommercial-NoDerivatives 4.0 (CC BY-NC-ND) International License.



**Figure 1.** An 84-year-old female with a known case of right breast cancer who underwent surgery followed by radiotherapy 10 years ago and now presented with a right axillary mass. The patient was referred for Tc-99m methylene diphosphonate (MDP) bone scan to rule out bone metastasis. The bone scan shows intense tracer uptake in the right thoracic region corresponding to the site of the calcified soft tissue mass in the right chest wall. Linearly increased tracer uptake is also seen in the L1 vertebra at the site of partial collapse. No evidence of bone secondaries. Ultrasonography showing a solid mass along the right lateral chest wall with ill-defined borders containing coarse calcifications and internal vascularity.



**Figure 2.** Biopsy of the calcified soft tissue mass showing malignant spindle cell tumor with hyperchromatic nuclei on H&E (A). (B-D) Immunostains demonstrate that the tumor cells are immunoreactive with smooth muscle cell differentiation antibodies desmin (B), smooth muscle actin (C), and H-caldesmon (D). Given the localization of the tumor not in the breast parenchyma and the fact that the patient received radiotherapy at the site of the tumor almost 10 years ago and no history of malignant phyllodes and metaplastic carcinoma, the histological features and the immunoprofile conform to radiotherapy-induced leiomyosarcoma in clinical settings.

Radiation-induced sarcoma (RIS) is a rare type of cancer that develops in the radiation field of a previous radiation therapy treatment. It is a long-term complication of radiation therapy that typically occurs years after the initial treatment (1). The exact mechanisms underlying the development of RISs are not fully understood. However, radiation exposure can cause genetic mutations or damage to DNA within normal cells, leading to the development of cancerous cells over time. The incidence rates of RISs in breast cancer patients typically range from 0.03% to 0.3% (3 to 30 cases per 10,000 patients) over a period of 10 to 20 years following radiation therapy (2). One study reported a cumulative incidence of 0.07% 5 years after irradiation, 0.27% at 10 years, and 0.48% at 15 years; the 5-year survival rate was 36% (3).

Tc-99m MDP is a bone imaging agent used for skeletal staging, but it can also be localized in extraosseous calcifying lesions. The reported mechanisms include (a) local tissue necrosis or damage leading to increased calcium deposition in the tissue, (b) hyperemia, (c) altered capillary permeability, (d) adsorption onto tissue calcium, (e) presence of iron deposits, and (f) binding to enzyme receptors or denatured proteins (4,5). Significantly increased MDP uptake by extraosseous soft tissue tumors is associated with poor differentiation in both children and adults (6). Extra-osseous tracer uptake is common on Tc-99m MDP, and these non-osseous findings may occasionally alter diagnosis and subsequent management. In hybrid imaging, anatomical localization with computed tomography often improves both the specificity of assessment of the bone lesion and soft tissue uptake. Clinical history and familiarity with typical imaging appearances are crucial for distinguishing soft tissue masses.

## Ethics

**Informed Consent:** Informed consent was obtained from the patient.

## Authorship Contributions

Surgical and Medical Practices: S.U., A.J., K.A.R., Z.N., S.K., V.V.J., Concept: S.U., A.J., K.A.R., Design: S.U., Data Collection or Processing: S.U., S.K., V.V.J., Analysis or Interpretation: S.U., A.J., Z.N., Literature Search: S.U., Writing: S.U., A.J., K.A.R.

**Conflict of Interest:** No conflicts of interest were declared by the authors.

**Financial Disclosure:** The authors declare that this study has received no financial support.

## References

- Hall EJ, Wu CS. Radiation-induced second cancers: the impact of 3D-CRT and IMRT. *Int J Radiat Oncol Biol Phys* 2003;56:83-88.
- Di Lalla V, Tolba M, Khosrow-Khavar F, Baig A, Freeman C, Panet-Raymond V. Radiation-induced sarcomas of the breast: a review of a 20-year single-center experience. *Cureus* 2023;15:e38096.
- Kirova YM, Vilcoq JR, Asselain B, Sastre-Garau X, Fourquet A. Radiation-induced sarcomas after radiotherapy for breast carcinoma: a large-scale single-institution review. *Cancer* 2005;104:856-863.
- Usmani S, Ahmed N, Muzaffar S, Al Kandari F. Extensive extramedullary hematopoiesis in thalassemia: soft tissue uptake on 99mTc-MDP SPECT/CT. *Clin Nucl Med* 2020;45:e459-e460.
- Usmani S, Gnanasegaran G, Marafi F, Esmail A, Ahmed N, Van den Wyngaert T. The clinical significance of incidental soft tissue uptake on whole body 18F-sodium fluoride bone PET-CT. *Clin Radiol* 2019;74:95-110.
- Liu S, Xie J, Yu F, Cai H, Wu F, Zheng H, Ma C, Lv Z, Wang H. 99mTc-methylene diphosphonate uptake in soft tissue tumors on bone scintigraphy differs between pediatric and adult patients and is correlated with tumor differentiation. *Cancer Manag Res* 2020;12:2449-2457.