



Isolated Diffuse Bone Marrow Metastases From Signet-ring Cell Gastric Carcinoma

Taşlı Yüzük Hücreli Mide Karsinomunun İzole Yaygın Kemik İliği Metastazları

© Tsz-Kit Chow

Tuen Mun Hospital, Clinic of Radiology and Nuclear Medicine, Nuclear Medicine Unit, Hong Kong, China

Abstract

A 71-year-old female patient with a known history of signet-ring cell carcinoma presented with diffuse bone pain and anemic symptoms. An ¹⁸F-fluorodeoxyglucose (FDG) positron emission tomography/computed tomography study revealed diffuse heterogeneous hypermetabolic sclerotic lesions in the axial and proximal appendicular skeleton. No other ¹⁸F-FDG-avid lesions were detected. Subsequent bone marrow biopsy confirmed the diagnosis of metastatic carcinoma originating from the gastric primary site. Palliative treatment was initiated; however, the patient's condition deteriorated, and she succumbed to the disease two months later.

Keywords: Bone marrow metastasis, signet-ring cell gastric carcinoma, ¹⁸F-FDG PET/CT

Öz

Bilinen taşlı yüzük hücreli karsinom öyküsü olan 71 yaşında kadın hasta, yaygın kemik ağrısı ve anemik semptomlarla başvurdu. ¹⁸F-florodeoksiglukoz (FDG) pozitron emisyon tomografisi/bilgisayarlı tomografi görüntülemesinde, aksiyal ve proksimal apendiküler iskelette yaygın heterojen hipermetabolik sklerotik lezyonlar saptandı. Başka hiçbir FDG avid lezyonu tespit edilmedi. Daha sonra yapılan kemik iliği biyopsisi primer olarak mideden kaynaklanan metastatik karsinom tanısını doğruladı. Palyatif tedavi başlandı; ancak hastanın durumu kötüleşti ve iki ay sonra hasta öldü.

Anahtar kelimeler: Kemik iliği metastazi, taşlı yüzük hücreli mide karsinomu, ¹⁸F-FDG PET/CT

Address for Correspondence: Tsz-Kit Chow MD, Tuen Mun Hospital, Clinic of Radiology and Nuclear Medicine, Nuclear Medicine Unit, Hong Kong, China

Phone: 852-38942527 **E-mail:** ctk594@ha.org.hk ORCID ID: orcid.org/0000-0002-1736-8771

Received: 17.10.2023 **Accepted:** 29.12.2023 **Epub:** 09.02.2024



Copyright© 2024 The Author. Published by Galenos Publishing House on behalf of the Turkish Society of Nuclear Medicine. This is an open access article under the Creative Commons Attribution-NonCommercial-NoDerivatives 4.0 (CC BY-NC-ND) International License.

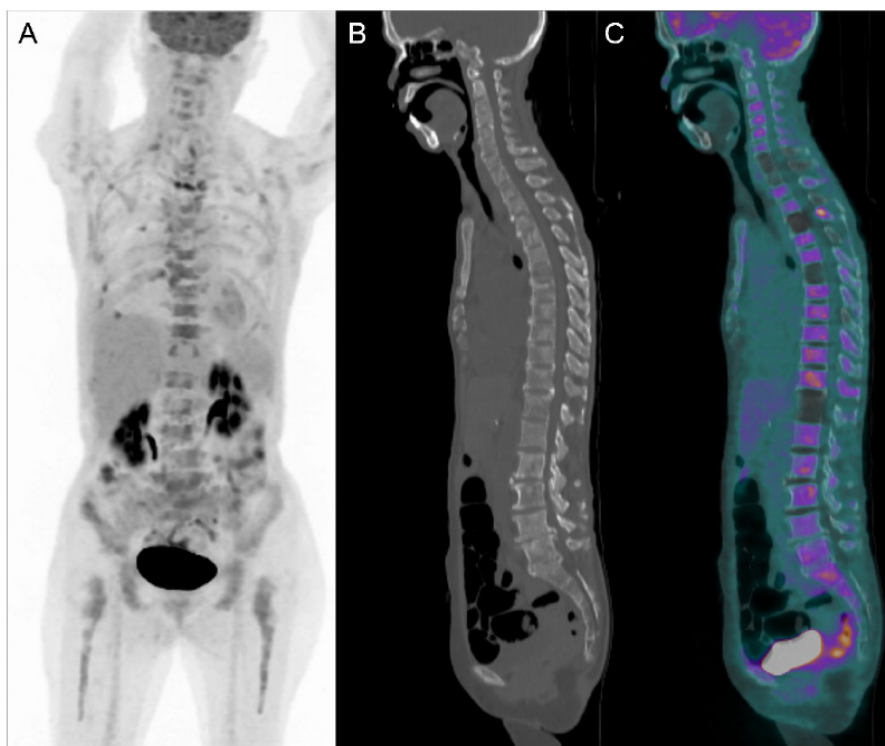


Figure 1. A 71-year-old female patient with a history of signet-ring cell gastric carcinoma (SRCC) (tumor, node, metastasis stage: pT1aN0M0) presented with diffuse bone pain and anemic symptoms. She underwent distal radical gastrectomy and extended lymph node dissection 6 years ago with no evidence of disease recurrence. She was referred for ^{18}F -fluorodeoxyglucose (FDG) positron emission tomography/computed tomography (PET/CT) for evaluation. Maximum intensity projection PET revealed diffuse heterogeneous uptake in the axial and proximal appendicular skeleton (A). Sagittal CT and fusion images demonstrated multiple mildly ^{18}F -FDG-avid sclerotic lesions in the spine (B, C). No other ^{18}F -FDG-avid lesions were detected. Subsequent bone marrow biopsy revealed metastatic carcinoma of gastric origin. She received palliative treatment and died two months later. SRCC of the stomach is a subtype of poorly cohesive gastric carcinoma, comprising 17% of all cases of gastric cancer (1). Gastric cancer is classified as SRCC if more than 50% of the tumor cells are scattered malignant cells containing intracytoplasmic mucin (2). Patients with SRCC are more likely to present at a later stage, have a poorer tumor grade, and have a similar prognosis compared with other gastric adenocarcinoma (3,4,5). SRCC of the stomach more commonly metastasizes to the peritoneum and bone and less frequently to the lymph nodes, lungs, and liver compared with other histologic types (2,6,7). Isolated diffuse metastatic involvement of the bone marrow in SRCC of the stomach is highly uncommon (8).

Ethics

Informed Consent: Informed consent was obtained from the patient.

Peer-review: Externally peer-reviewed.

Financial Disclosure: The author declared that this study received no financial support.

References

1. Benesch MGK, Mathieson A. Epidemiology of Signet Ring Cell Adenocarcinomas. *Cancers (Basel)* 2020;12:1544.
2. Zhang C, Liu R, Zhang WH, Chen XZ, Liu K, Yang K, Chen XL, Zhao LY, Chen ZX, Zhou ZG, Hu JK. Difference Between Signet Ring Cell Gastric Cancers and Non-Signet Ring Cell Gastric Cancers: A Systematic Review and Meta-Analysis. *Front Oncol* 2021;11:618477.
3. Taghavi S, Jayarajan SN, Davey A, Willis AI. Prognostic significance of signet ring gastric cancer. *J Clin Oncol* 2012;30:3493-3498.
4. Zaafouri H, Jouini R, Khedhiri N, Khanchel F, Cherif M, Mesbahi M, Daghmour A, Mahmoudi W, Akremi S, Sabbah M, Benzarti Y, Hadded D, Gargouri D, Bader MB, Maamer AB. Comparison between signet-ring cell carcinoma and non-signet-ring cell carcinoma of the stomach: clinicopathological parameters, epidemiological data, outcome, and prognosis-a cohort study of 123 patients from a non-endemic country. *World J Surg Oncol* 2022;20:238.
5. Efaled B, Kadi M, Tahiri L, Lahmidani N, Hassani KM, Bouhaddouti HE, Benbrahim Z, Adil IS, Chbani L. Gastric Signet Ring Cell Carcinoma: A Comparative Analysis of Clinicopathologic Features. *Cancer Control* 2020;27:1073274820976596.
6. Riihimäki M, Hemminki A, Sundquist K, Sundquist J, Hemminki K. Metastatic spread in patients with gastric cancer. *Oncotarget* 2016;7:52307-52316.
7. Zhao S, Lv L, Zheng K, Tian Y, Zheng JC, Jiang CG. Prognosis and Biological Behavior of Gastric Signet-Ring Cell Carcinoma Better or Worse: A Meta-Analysis. *Front Oncol* 2021;11:603070.
8. Dittus C, Mathew H, Malek A, Negroiu A. Bone marrow infiltration as the initial presentation of gastric signet ring cell adenocarcinoma. *J Gastrointest Oncol* 2014;5:E113-E116.